



Cornea : donor history



NL donor and processing :Autopsy after donation of corneas showed deceased donor suffered from endocarditis/pericarditis

Patient Greece : Cornea already transplanted

Reaction or event ?

Serious?

What should you do as TE?

What should the Hospital do?



Cornea : donor history



NL donor and processing :Autopsy after donation of corneas showed deceased donor suffered from endocarditis/pericarditis

Patient Greece : Cornea already transplanted

Reaction or event ?

Event

Serious?

No

What should you do as TE?

check cultures/ inform txp center/inform CA/TRIP voluntary

What should Hospital do?

Monitor patient/ collaborate in investigation TE



Tendon tears



NL patient : Achillis tendon tears during OP pre-implantation.

Donor + processor US : aseptic processing; gammaradiation. Second tendon in same period from same processor (different donor) in NL. Two more tears in other countries same processor

Reaction or event ?

Serious?

What would you do as hospital?

What would you do as TE?



Tendon tears

NL patient : Achillis tendon tears during OP pre-implantation.

Donor + processor US : aseptic processing; gamma radiation. Second tendon in same period from same processor (different donor) in NL. Two more tears in other countries same processor

Reaction or event ?

Event/Reaction

Serious?

Yes

What would you do as hospital?

Save tendon for investigation/ report to NL distributor

What would you do as TE?

Report to TE in the US, investigate /Report to NL



Heart valve rupture



NL patient : patient with endocarditis and sepsis dies during OP due to bleeding around the stitches of human aortic valve. Surgeon considered aortic wall "weak" and damaged.

Donor + processor DE: No morphological deficiencies found

Reaction or event ?

Serious?

What would you do as to hospital?

What would you do as TE?



Heart valve rupture



NL patient : patient with endocarditis and sepsis dies during OP due to bleeding around the stitches of human aortic valve. Surgeon considered aortic wall "weak" and damaged.

Donor + processor DE: No morphological deficiencies found

Reaction or event ?

Serious?

What would you do as to hospital?

What would you do as TE?

Reaction

Yes

report to TE Germany/ Report to CA/TRIP on voluntary bases

Report to CA Germany

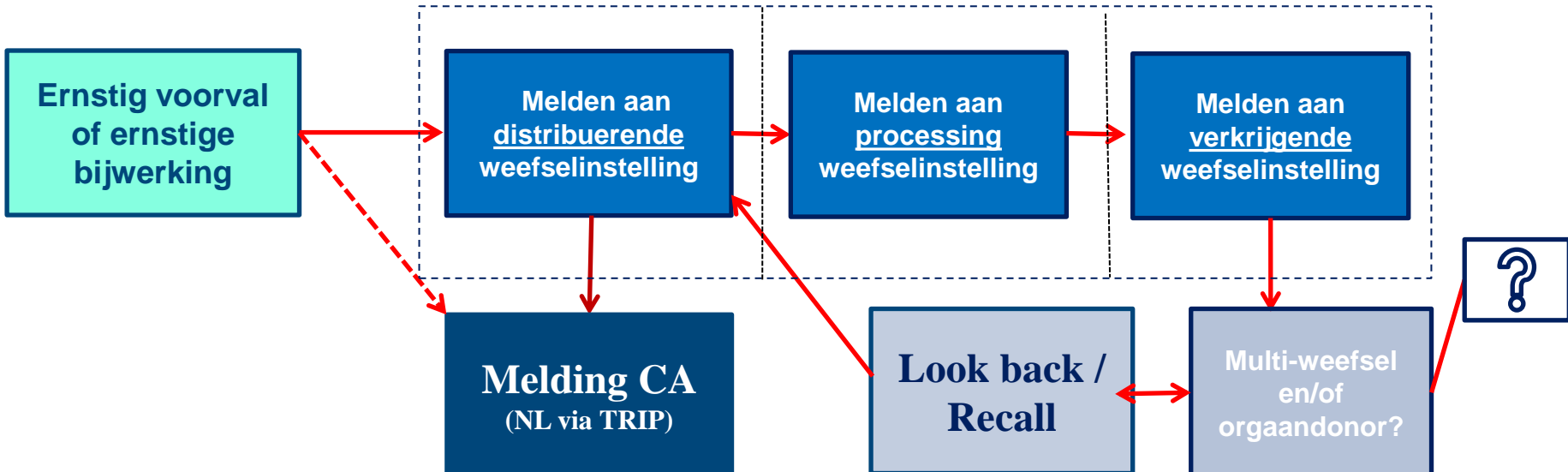
Melden aan de CA binnen EU

Weefselinstelling



De bewerkende weefselinstelling meldt bij CA in eigen land

Ziekenhuis/kliniek/behandelaar



De distribuerende weefselinstelling en eventueel het ziekenhuis meldt bij CA in eigen land

Clusters of reports

Years	Clusters
2007-2016	Identification and selection errors
2007-2016	Loss of gametes and embryos
2010-2016	Leaking or ruptured bags for HSC
2011-2012	Hazes after cornea transplants
2015-2016	Problems with pipettes in fertility laboratories